

Digital Breast Tomosynthesis and Synthetic 2D Mammography versus Digital Mammography: Evaluation in a Population-based Screening Program¹

Solveig Hofvind, PhD
Tone Hovda, MD
Åsne S. Holen, MSc
Christoph I. Lee, MD, MS
Judy Albertsen, MD
Hilde Bjørndal, MD
Siri H. B. Brandal, MD
Randi Gullien, MSc
Jon Lømo, MD, PhD
Daehoon Park, MD, PhD
Linda Romundstad, MD
Pål Suhrke, MD, PhD
Einar Vigeland, MD
Per Skaane, MD, PhD

Purpose:

To compare the performance of digital breast tomosynthesis (DBT) and two-dimensional synthetic mammography (SM) with that of digital mammography (DM) in a population-based mammographic screening program.

Materials and Methods:

In this prospective cohort study, data from 37 185 women screened with DBT and SM and from 61 742 women screened with DM as part of a population-based screening program in 2014 and 2015 were included. Early performance measures, including recall rate due to abnormal mammographic findings, rate of screen-detected breast cancer, positive predictive value of recall, positive predictive value of needle biopsy, histopathologic type, tumor size, tumor grade, lymph node involvement, hormonal status, Ki-67 level, and human epidermal growth factor receptor 2 status were compared in women who underwent DBT and SM screening and in those who underwent DM screening by using χ^2 tests, two-sample unpaired *t* tests, and tests of proportions.

Results:

Recall rates were 3.4% for DBT and SM screening and 3.3% for DM screening ($P = .563$). DBT and SM screening showed a significantly higher rate of screen-detected cancer compared with DM screening (9.4 vs 6.1 cancers per 1000 patients screened, respectively; $P < .001$). The rate of detection of tumors 10 mm or smaller was 3.2 per 1000 patients screened with DBT and SM and 1.8 per 1000 patients screened with DM ($P < .001$), and the rate of grade 1 tumors was 3.3 per 1000 patients screened with DBT and SM versus 1.4 per 1000 patients screened with DM ($P < .001$). On the basis of immunohistochemical analyses, rates of lymph node involvement and tumor subtypes did not differ between women who underwent DBT and SM screening and those who underwent DM screening.

Conclusion:

DBT and SM screening increased the detection rate of histologically favorable tumors compared with that attained with DM screening.

©RSNA, 2018

Online supplemental material is available for this article.

¹ From the Cancer Registry of Norway, PO Box 5313, Majorstuen, Oslo 0304, Norway (S.H., Å.S.H.); Oslo and Akershus University College of Applied Sciences, Oslo, Norway (S.H.); Departments of Radiology (T.H., H.B., L.R.) and Pathology (D.P.), Vestre Viken Hospital, Drammen, Norway; University of Washington School of Medicine, Seattle, Wash (C.I.L.); University of Washington School of Public Health, Seattle, Wash (C.I.L.); Hutchinson Institute for Cancer Outcomes Research, Seattle, Wash (C.I.L.); Departments of Radiology (J.A., E.V.) and Pathology (P. Suhrke), Vestfold Hospital, Tønsberg, Norway; and Departments of Radiology and Nuclear Medicine (S.H.B.B., R.G., P. Skaane) and Pathology (J.L.), Oslo University Hospital, Oslo, Norway. Received June 15, 2017; revision requested August 14; revision received January 4, 2018; accepted January 5. Address correspondence to S.H. (e-mail: solveig.hofvind@kretregisteret.no).

Studies have shown that use of digital breast tomosynthesis (DBT) in combination with digital mammography (DM) in breast cancer screening programs increases the cancer detection rate compared with that attained with DM alone, while results for recalls have been somewhat conflicting (1–7). The drawbacks of combination screening with DBT and DM include increased radiation exposure to patients, extended compression time, increased radiologist interpretation time, and the need for increased data storage space (8–10). In addition, it is unknown if the additional cancers detected represent clinically meaningful cancers or if they are dormant or slow-growing tumors that never would have become clinically important within the woman's lifetime; the latter are usually referred to as overdiagnosis.

According to the International Agency for Research on Cancer, there is currently insufficient evidence to implement (a) DBT and DM and (b) DM alone in breast cancer screening (8). This statement is supported by multiple systematic reviews and meta-analyses (9,11,12). Variable performance measures across facilities and insufficient knowledge about the prognostic and predictive tumor characteristics of

screen-detected cancers and the rate of interval cancers have been cited as challenges (8,10).

Software to create synthetic mammographic (SM) images from DBT raw data are now available, eliminating the need for concurrent DM image acquisition and reducing concern related to the increased radiation dose from combined DBT and DM screening (13–17). Early reports suggest that the rate of screen-detected breast cancer does not differ between (a) DBT and SM screening and (b) DBT and DM screening (14,15). Our study objective was to investigate early screening performance measures attained with DBT and SM versus those attained with DM alone in a population-based screening program.

Materials and Methods

This study was approved by the Data Protection Official of the Cancer Registry of Norway. The Norwegian Breast Cancer Screening Program is described in detail elsewhere (18). In brief, a postal or digital letter is sent to invite all Norwegian women aged 50–69 years to undergo biennial mammographic screening, with a stated time and place for the examination. The women are screened at 26 stationary and four mobile screening units, and image interpretation, consensus reading, and diagnostic examinations for recalled women are performed at 16 regional breast centers. The Cancer Registry of Norway administers the program.

This prospective population-based cohort study included screening examinations performed at three independent breast centers in three neighboring screening areas in the southeastern part of the country. All centers are part of the Norwegian Breast Cancer Screening Program. The radiologists who performed screen reading in the study period had varying degrees of experience with such work (Table E1 [online]). However, the centers showed comparable cancer detection rates and histologic tumor characteristics prior to the study period (date range, 2007–2009) (Table E2 [online]).

A total of 98927 women were prospectively included in this study and underwent screening between February 1, 2014, and January 31, 2016, which corresponded to one screening round. Women attending the stationary screening unit in Oslo ($n = 37185$) were screened with DBT and SM (Dimensions; Hologic, Bedford, Mass). Among these women, a total of 7250 (19.5%) had their first (prevalent) screening examination in the program during the study period. Women attending screening in Vestfold and Vestre Viken were screened with DM. In Vestfold, the screening examinations took place at the stationary unit (Dimensions; Hologic), while in Vestre Viken, women were screened at two stationary units (Mammomat Inspiration; Siemens, Erlangen, Germany) and one mobile unit (Seno Essential, GE Healthcare, Buc France). Data from Vestfold and Vestre Viken were combined and will hereafter be referred to as the DM group ($n = 61742$). During the study period, a total of 9517 (15.4%) women in the DM group were prevalently screened.

Images from the screening examinations were independently interpreted

Implications for Patient Care

- In a population-based breast cancer screening program, digital breast tomosynthesis with synthetic mammography depicted more cancers than did digital mammography.
- Digital breast tomosynthesis with synthetic mammography depicts more early stage breast cancers than does digital mammography.
- Invasive breast cancers detected with digital breast tomosynthesis and synthetic mammography had more favorable tumor characteristics (including smaller tumor diameter and more grade 1 tumors) than did cancers detected with digital mammography.

<https://doi.org/10.1148/radiol.2018171361>

Content code: **BR**

Radiology 2018; 287:787–794

Abbreviations:

DBT = digital breast tomosynthesis
 DCIS = ductal carcinoma in situ
 DM = digital mammography
 Her2 = human epidermal growth factor receptor 2
 PPV-1 = positive predictive value of recalls
 PPV-3 = positive predictive value of performed needle biopsies
 SM = synthetic mammography

Author contributions:

Guarantors of integrity of entire study, S.H., P. Skaane; study concepts/study design or data acquisition or data analysis/interpretation, all authors; manuscript drafting or manuscript revision for important intellectual content, all authors; approval of final version of submitted manuscript, all authors; agrees to ensure any questions related to the work are appropriately resolved, all authors; literature research, S.H., T.H., Å.S.H., C.I.L., P. Skaane; clinical studies, all authors; statistical analysis, S.H., Å.S.H., C.I.L.; and manuscript editing, all authors

Conflicts of interest are listed at the end of this article.

Table 1

Rates of Abnormal Mammographic Findings (Recall), Screen-detected Breast Cancer and Positive Predictive Values of Recalls and Needle Biopsies in Women Screened with Combined Digital Breast Tomosynthesis and Synthetic Two-dimensional Mammography or Digital Mammography

Characteristic	Screening with DBT and SM (n = 37 185)	Screening with DM (n = 61 742)	Overall (n = 98 927)	P Value*
Age (y)				
Average	59.2	59.4	59.3	<.001
Median	59.0	59.0	59.0	<.001
Recall†	1253 (3.4)	2037 (3.3)	3290 (3.3)	.563
Screen-detected cancer‡				
Invasive breast cancer	283 (7.6)	329 (5.3)	612 (6.2)	<.001
Ductal carcinoma in situ	65 (1.7)	50 (0.8)	115 (1.2)	<.001
Total	348 (9.4)	379 (6.1)	727 (7.3)	<.001
Positive predictive value of recalls (%)§	27.8	18.6	22.1	<.001
Positive predictive value of performed needle biopsies (%)	53.7	38.6	44.6	<.001

* P value was determined by comparing women who underwent digital breast tomosynthesis (DBT) and synthetic mammography (SM) with those who underwent digital mammography (DM).

† Data are number of abnormal mammographic findings. Data in parentheses are percentages.

‡ Data are number of patients. Data in parentheses are rate per 1000 women screened.

§ Ductal carcinoma in situ and invasive breast cancer among women recalled because of abnormal mammographic findings.

|| Ductal carcinoma in situ and invasive breast cancer among women who underwent needle biopsy after being recalled because of abnormal mammographic findings.

by two radiologists at each breast center. Each breast was given a score of 1–5 by each radiologist, with a score of 1 indicating screening was negative for abnormalities; 2, screening findings were probably benign; 3, screening findings raised intermediate suspicion; 4, screening findings were probably malignant; and 5, screening findings were highly suspicious for malignancy. If one or both radiologists had assigned a score of 2 or higher, a consensus or arbitration meeting was held to determine whether to call the woman back for further assessment (recall) or not. Prior examinations were available for initial screening interpretation and at the consensus meeting. The screening examinations included in this study were read by breast radiologists working at one of the three breast centers (14 radiologists in Oslo, four in Vestfold, six in Vestre Viken). Experience in screen reading DM before the study started varied from 0 to 14 years in Oslo (mean, 4 years), from 6 to 10 years in

Vestfold (mean, 9 years), and from 0 to 5 years in Vestre Viken (mean, 3 years). Experience in screen reading DBT as performed in Oslo varied from 2 months to 3 years (mean, 1.2 years) (Table E1 [online]). All breast biopsy and surgical specimens were examined by pathologists with at least 5 years of experience. Pathologic analysis was performed in the breast center, and the pathologists worked in close collaboration with the radiologists. All data from screening and diagnostic examinations were reported by radiologists and pathologists to the Cancer Registry of Norway for pooling and analysis.

Early performance measures were defined as recall rate, rate of screen-detected breast cancer, positive predictive value of recalls (PPV-1), positive predictive value of performed needle biopsies (PPV-3), and prognostic and predictive tumor characteristics.

Recall rate was defined as the proportion of women recalled because of abnormal mammographic findings

among those screened. The rate of screen-detected breast cancer was estimated as the number of women with breast cancer (ductal carcinoma in situ [DCIS] and invasive breast cancer separately and in total) diagnosed after a positive screening examination. PPV-1 was calculated as the percentage of breast cancer cases detected among those recalled. PPV-2 (the percentage of recalled women recommended to have needle biopsy) and PPV-3 are almost identical in Norway; thus, PPV-2 is not given and PPV-3 was estimated as the percentage of breast cancer detected among women recalled who underwent needle biopsy during further assessment. Histopathologic tumor characteristics were based on surgical biopsy reports. Histologic type was defined as DCIS, invasive ductal carcinoma, invasive lobular carcinoma, invasive tubular carcinoma, or other invasive carcinomas. Prognostic tumor characteristics for invasive tumors included tumor diameter (≤ 10 mm, > 10 mm to ≤ 20 mm, and > 20 mm), lymph node involvement (negative or positive), and histologic grade (grade 1–3). Predictive tumor characteristics included estrogen and progesterone receptor status (positive or negative), human epidermal growth factor receptor 2 (Her2) status (positive or negative), and Ki-67 protein level ($< 30\%$ or $\geq 30\%$). This information was used to classify the invasive tumors into subtypes (luminal A, luminal B Her2 negative, luminal B Her2 positive, Her2 positive, and triple negative) (19).

Descriptive statistics were used to make comparisons between the two groups, (a) DBT and SM and (b) DM.

Two-proportion z tests and two-sample unpaired t tests were used to compare early performance measures and histopathologic tumor characteristics between women screened with DBT and SM and those screened with DM. $P < .05$ was considered indicative of a significant difference. When we compared histopathologic tumor characteristics, we adjusted for multiple comparisons by using the Bonferroni correction, and we used $P = .003$ (0.05/17) as the threshold for statistical significance.

Stata software (version 14; Stata, College Station, Tex) was used for all data analyses.

Results

Average and median age were 59.2 and 59.0 years, respectively, in the 37 185 women screened with DBT and SM and 59.4 and 59.0 years, respectively, in the 61 742 women screened with DM ($P < .001$) (Table 1).

Recall rate was 3.4% (1253 of 37 185) in the DBT and SM group and 3.3% (2037 of 61 742) in the DM group ($P = .562$) (Table 1). No significant difference in recall rate between the DBT and SM group and the DM group was observed for either prevalent (DBT and SM, 7.4% [537 of 7250]; DM, 7.6% [726 of 9517]; $P = .591$) or incident (DBT and SM, 2.4% [716 of 29935]; DM, 2.5% [1312 of 52225]; $P = .284$) screening.

Overall, 348 breast cancers were detected because of abnormal DBT and SM screening results and 379 were detected because of abnormal DM screening results. The screen-detected cancer detection rate was 9.4 per 1000 women screened (348 of 37 185 women) in the DBT and SM group and 6.1 per 1000 women screened (379 of 61 742 women) in the DM group ($P < .001$). PPV-1 and PPV-3 were significantly higher in the DBT and SM group than in the DM group (27.8% vs 18.6% for PPV-1, 53.7% vs 38.6% for PPV-3; $P < .001$ for both).

The rate of screen-detected DCIS and the rate of invasive breast cancer were significantly higher in the DBT and SM group than in the DM group (Table 1). Furthermore, the rate of tubular breast carcinoma was significantly higher in women who underwent DBT and SM than in those who underwent DM after correcting for multiple comparisons (0.8 per 1000 women screened vs 0.1 per 1000 women screened, $P < .001$) (Table 2). The rate of invasive tumors 10 mm in diameter or smaller was 3.2 per 1000 women screened with DBT and SM versus 1.8 per 1000 women screened with DM ($P < .001$) (Table 2). The rate of grade 1 tumors was 3.3 per 1000

Table 2

Rates of Histologic Type and Prognostic and Predictive Tumor Characteristics of Cancers in Women Screened with Digital Breast Tomosynthesis including Synthetic Two-dimensional Mammography versus those in Women Screened with Digital Mammography

Characteristic	Screening with DBT and SM (n = 37 185)	Screening with DM (n = 61 742)	Overall (n = 98 927)	P Value
Histologic type				
Ductal carcinoma in situ	65 (1.7)	50 (0.8)	115 (1.2)	<.001*
Invasive ductal carcinoma	208 (5.6)	272 (4.4)	480 (4.9)	.014
Invasive lobular carcinoma	42 (1.1)	45 (0.7)	87 (0.9)	.061
Tubular carcinoma	28 (0.8)	6 (0.1)	34 (0.3)	<.001*
Other invasive carcinomas	5 (0.1)	6 (0.1)	11 (0.1)	.590
Tumor diameter				
≤10 mm	119 (3.2)	109 (1.8)	228 (2.3)	<.001*
>10 to ≤20 mm	122 (3.3)	154 (2.5)	279 (2.8)	.030
>20 mm	38 (1.0)	57 (0.9)	95 (1.0)	.747
Missing	4	9	13	...
Lymph node involvement				
Positive	36 (1.0)	45 (0.7)	81 (0.8)	.341
Missing	11	7	18	...
Histologic grade				
Grade 1	123 (3.3)	86 (1.4)	209 (2.1)	<.001*
Grade 2	130 (3.5)	186 (3.0)	316 (3.2)	.233
Grade 3	28 (0.8)	56 (0.9)	84 (0.8)	.376
Missing	2	1	3	...
Subtype				
Luminal A	158 (4.2)	198 (3.2)	356 (3.6)	...
Luminal B Her2 negative	98 (2.6)	91 (1.5)	189 (1.9)	...
Luminal B Her positive	13 (0.3)	19 (0.3)	32 (0.3)	...
Her2 positive	1 (0.03)	6 (0.1)	7 (0.1)	...
Triple negative	10 (0.3)	12 (0.2)	22 (0.2)	...
Missing	3	3	6	...

Note.—Unless otherwise indicated, data are number of patients. Data in parentheses are rate per 1000 women screened.

* Difference is significant after Bonferroni correction.

women screened with DBT and SM versus 1.4 per 1000 women screened with DM ($P < .001$). The rates did not differ significantly for grade 2 ($P = .233$) or 3 ($P = .376$) tumors. There were no significant differences in the rate of lymph node involvement or in tumor immunohistochemical subtypes in women screened with DBT and SM versus those screened with DM (Table 2).

Discussion

We identified a significantly higher rate of screen-detected breast cancer in women screened with DBT and SM than in women screened with DM in

the Norwegian Breast Cancer Screening Program. The incremental cancer detection rate was higher for both DCIS and invasive breast cancers. These differences were observed in everyday routine screening settings, and the study design ensured an acceptable radiation dose and reduced examination time (compared with a combined examination with both DBT and DM) in women screened with DBT and SM. Typical mammographic features identified with DBT and SM were spiculated masses and spiculated masses with desmoplastic reaction (Figs 1–3).

Our higher rate of screen-detected cancer supports results from analyses

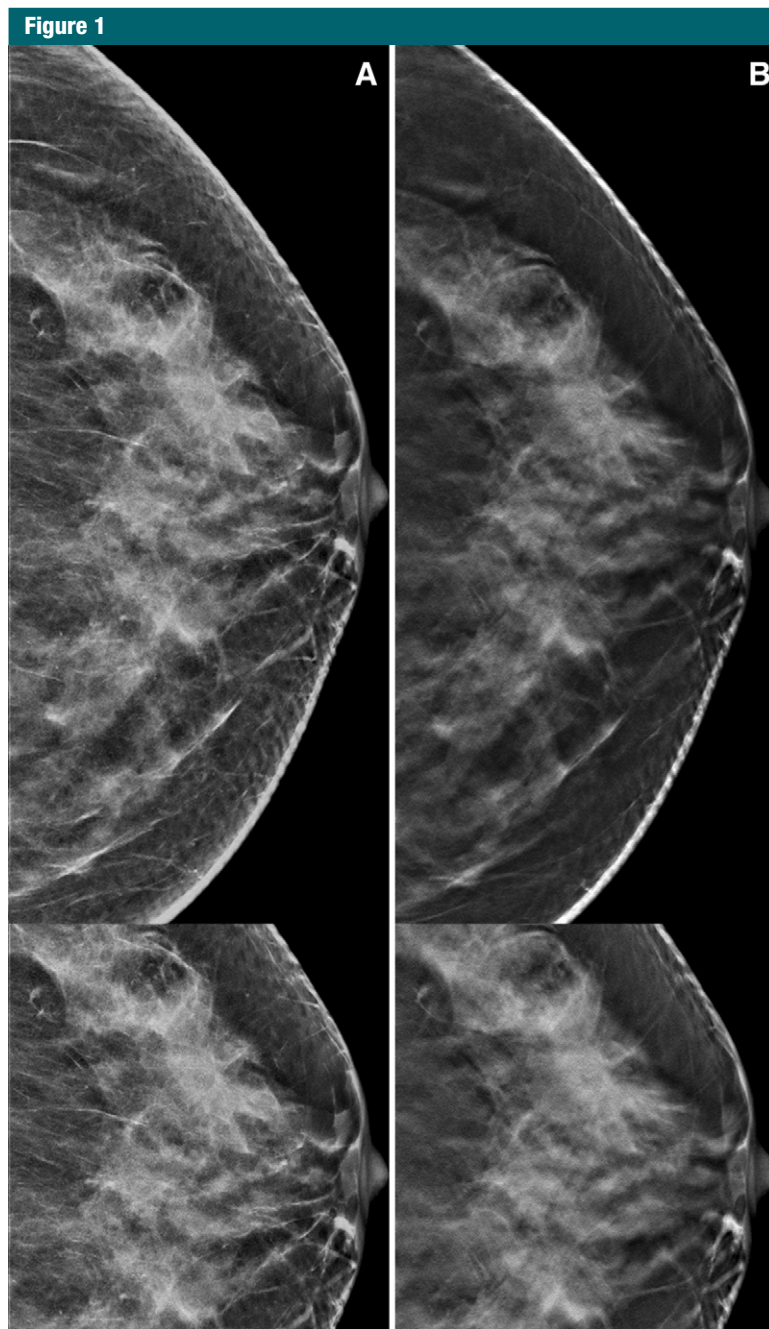


Figure 1: Screening mammograms of the left breast in a 51-year-old woman. Bottom images are magnifications and show the suspicious findings. *A*, Synthetic two-dimensional image shows normal dense breast parenchyma, except for a few nonspecific microcalcifications. *B*, Digital breast tomosynthesis image shows a desmoplastic reaction (architectural distortion) that is highly suspicious for malignancy anterior to the fine microcalcifications. Histologic analysis revealed ductal carcinoma in situ (grade 3, 12-mm diameter).

with DBT and SM in other studies (14,15,17). We identified a significantly higher detection rate for both

invasive breast cancer and DCIS among women screened with DBT and SM. The increased DCIS detection rate was

somewhat surprising, since the detectability of suspicious microcalcifications with DBT versus that with DM has been questioned (16,20,21). Our study indicates that SM might be of sufficient quality to depict suspicious microcalcifications found to harbor DCIS.

Interestingly, recall rates did not differ significantly between the DBT and SM group and the DM group in the study period. Studies comparing combined DBT and DM screening with DM screening have different reading procedures and have shown conflicting results regarding recall rate when adding DBT to the screening procedure, especially in European studies in which the rate in general is substantially lower than that in the United States (10,22,23). However, the recall rate in Oslo was lower in the study period (DBT and SM) than in the period before the study (DM) (Table E2 [online]). Both PPV-1 and PPV-3 were significantly higher with DBT and SM screening than with DM screening. Similar recall rates for screening with DM and for screening with DBT and SM, combined with a higher value of both PPV-1 and PPV-3 for screening with DBT and SM, may indicate that screening with DBT and SM is a more effective screening tool than screening with DM.

An important issue is the clinical importance of the additional cancers detected with DBT and SM. In general, cancers detected with DBT and SM had smaller tumor diameter and were of a lower histologic grade than were those detected with DM. The rates of histologic grade 1 invasive cancers differed significantly, while the rates did not differ significantly for grade 2 or 3 invasive cancers. Furthermore, the proportion of tubular carcinomas, which usually represent less aggressive invasive carcinomas, was significantly higher in the DBT and SM group than in the DM group. The percentage of invasive ductal carcinoma grade 1 and tubular carcinoma combined was also higher in the DBT and SM group than in the DM group (Table E3 [online]). These results suggest increased detection of less aggressive invasive tumors when using DBT and SM compared with DM.

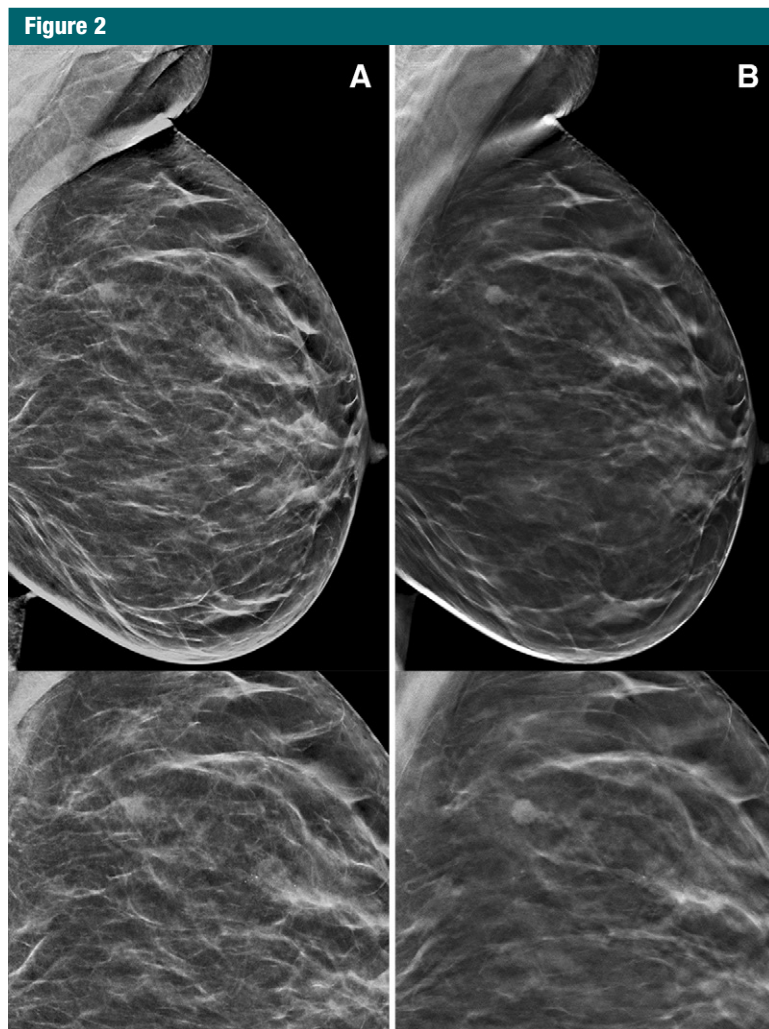


Figure 2: Screening mammograms of the left breast in a 56-year-old woman. Bottom images are magnifications and show the suspicious findings. *A*, Synthetic two-dimensional image shows segmental calcifications suspicious for ductal carcinoma in situ and a nonspecific round density. *B*, Digital breast tomosynthesis image shows a round mass with slightly spiculated margins consistent with breast cancer. The microcalcifications are highlighted and are better perceived on synthetic two-dimensional mammograms. Histologic analysis revealed invasive ductal carcinoma (grade 2, 6-mm diameter) posteriorly and ductal carcinoma in situ (grade 3, 25-mm diameter) anteriorly.

Detection of small and lower-grade tumors is sometimes referred to as overdiagnosis, and these lesions usually require less aggressive treatment than do larger higher-grade tumors. Some proportion of these tumors, however, may represent breast cancers that would otherwise not have become clinically apparent during a woman's lifetime, and detection and treatment of these cancers might not save women from breast

cancer-related death. Future studies exploring breast tumor growth and with access to long-term clinical follow-up data are needed to fully understand the complex issue related to detection and treatment of small slow-growing breast tumors associated with DBT and SM screening. Analysis and comparison of rates of interval breast cancer in women screened with DBT and SM and in those screened with DM during the

study period, as well as during the pre- and poststudy period, are necessary to fully understand and describe the issue of potential overdiagnosis. Results from several ongoing studies, including the large National Cancer Institute-sponsored Tomosynthesis Mammography Imaging Screening Trial (<https://ClinicalTrials.gov/NCT03233191>) may address these questions and help fill existing knowledge gaps related to use of DBT in screening for breast cancer. Furthermore, studies using equipment from other vendors may be needed to generalize our findings of increased sensitivity of DBT and SM.

Our study had some limitations. The three different breast centers represented different geographic areas with different screening and mammographic units; furthermore, these breast centers had a variety of radiologists and pathologists who interpreted images and pathologic findings at various workstations. The centers had comparable cancer detection rates in the prestudy period (date range, 2007–2009). The breast imaging experience level of the interpreting radiologists was generally high; however, experience with interpretation of DBT and SM images was variable. The majority of radiologists in the DM group performed screen reading before and during the study period. This was not the case in Oslo, where radiologists used DBT and SM and where the majority of radiologists had limited or no experience with DBT and SM screen reading. The most plausible harm from limited experience is increased interpretation time, increased recall rate, and decreased detection rate. This could indicate that the results would have differed even more for DM when compared with combined DBT and SM if only radiologists trained in DBT reading had been included.

The local pathologists examined each breast biopsy sample at their local center and made a diagnosis without any consensus. This procedure might represent a limitation; however, recent studies have shown acceptable agreement in local versus centralized breast pathology interpretations (24,25). Interreader variability among

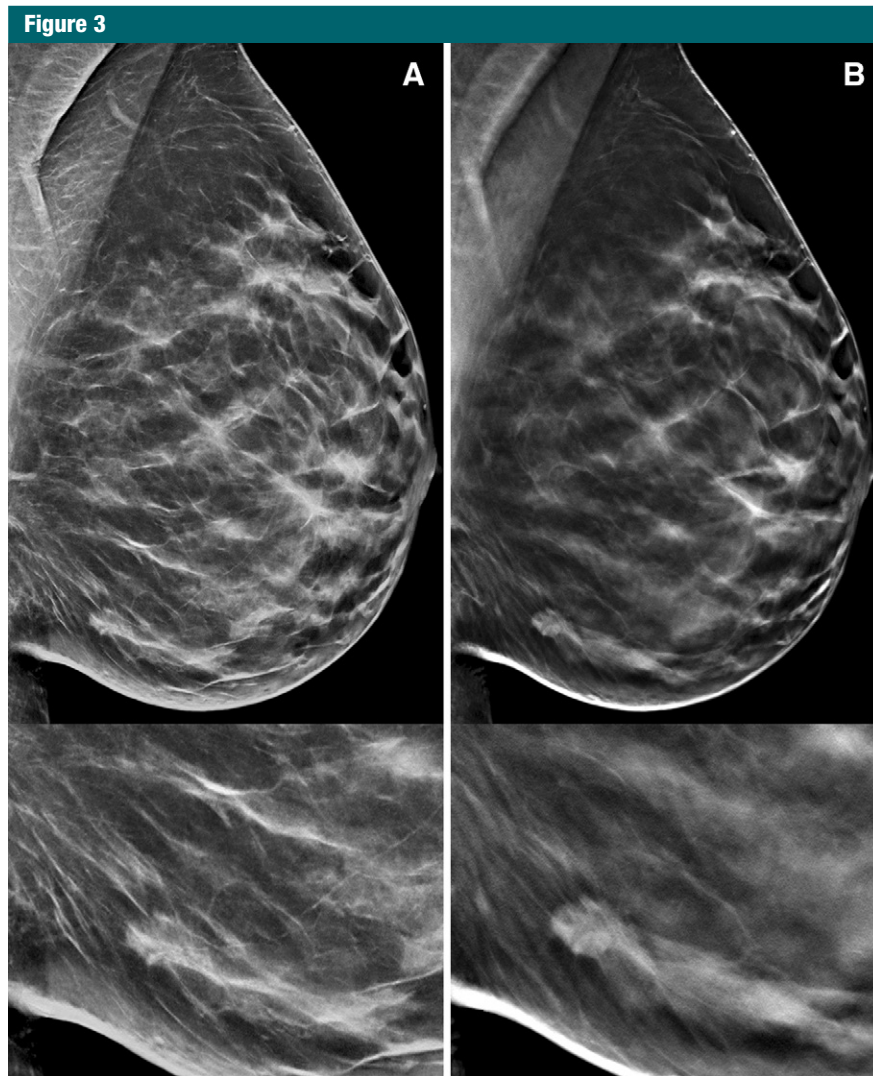


Figure 3: Screening mammograms of the left breast in a 50-year-old woman. Bottom images are magnifications and show the suspicious findings. *A*, Mediolateral oblique view shows several spotty densities but no obvious suspicious findings. *B*, Digital breast tomosynthesis image shows a slightly irregular mass with spiculations anteriorly, consistent with breast cancer. Histologic analysis revealed invasive ductal carcinoma (grade 2, 9-mm diameter) and ductal carcinoma in situ (grade 2).

radiologists and pathologists may influence variation in the early performance measures. A consensus-based radiologic review and reassessment of histologic specimens might also help clarify variability across sites and is currently in progress. Another limitation of our study was the lack of information about mammographic density, which could have shed an additional valuable light on the results. Finally, this study was performed in Norway, where biennial screening with independent double

reading and consensus is offered to women aged 50–69 years, a practice that is different from breast cancer screening offered in the United States. Screening regimen differences should be taken into account in the interpretation of these results.

In summary, our study showed the rate of screen-detected breast cancer was substantially higher in women screened with DBT and SM than in women screened with DM. Prognostic and predictive characteristics tended to

be more favorable in tumors detected with DBT and SM than in those detected with DM. A future investigation with long-term clinical follow-up data is needed to determine differences in the rate of interval breast cancer, differences in tumor characteristics, and differences in survival data for screening with DBT and SM compared with screening with DM.

Disclosures of Conflicts of Interest: **S.H.** Activities related to the present article: is the head of the Norwegian Breast Cancer Screening Program; is employed by the Cancer Registry of Norway. Activities not related to the present article: disclosed no relevant relationships. Other relationships: disclosed no relevant relationships. **T.H.** disclosed no relevant relationships. **A.S.H.** disclosed no relevant relationships. **C.L.L.** Activities related to the present article: disclosed no relevant relationships. Activities not related to the present article: received a grant from GE Healthcare. Other relationships: disclosed no relevant relationships. **J.L.A.** disclosed no relevant relationships. **H.B.** disclosed no relevant relationships. **S.H.B.B.** disclosed no relevant relationships. **R.G.** disclosed no relevant relationships. **J.L.** disclosed no relevant relationships. **D.P.** disclosed no relevant relationships. **L.R.** disclosed no relevant relationships. **P. Suhrke** disclosed no relevant relationships. **E.V.** disclosed no relevant relationships. **P. Skaane** Activities related to the present article: institution received equipment from and readers were supported by Hologic. Activities not related to the present article: disclosed no relevant relationships. Other relationships: disclosed no relevant relationships.

References

1. Skaane P, Bandos AI, Gullien R, et al. Comparison of digital mammography alone and digital mammography plus tomosynthesis in a population-based screening program. *Radiology* 2013;267(1):47–56.
2. Lång K, Andersson I, Rosso A, Tingberg A, Timberg P, Zackrisson S. Performance of one-view breast tomosynthesis as a stand-alone breast cancer screening modality: results from the Malmö Breast Tomosynthesis Screening Trial, a population-based study. *Eur Radiol* 2016;26(1):184–190.
3. Bernardi D, Ciatto S, Pellegrini M, et al. Prospective study of breast tomosynthesis as a triage to assessment in screening. *Breast Cancer Res Treat* 2012;133(1):267–271.
4. Friedewald SM, Rafferty EA, Rose SL, et al. Breast cancer screening using tomosynthesis in combination with digital mammography. *JAMA* 2014;311(24):2499–2507.

5. Greenberg JS, Javitt MC, Katzen J, Michael S, Holland AE. Clinical performance metrics of 3D digital breast tomosynthesis compared with 2D digital mammography for breast cancer screening in community practice. *AJR Am J Roentgenol* 2014;203(3):687–693.
6. Rose SL, Tidwell AL, Bujnoch LJ, Kushwaha AC, Nordmann AS, Sexton R Jr. Implementation of breast tomosynthesis in a routine screening practice: an observational study. *AJR Am J Roentgenol* 2013;200(6):1401–1408.
7. Yun SJ, Ryu CW, Rhee SJ, Ryu JK, Oh JY. Benefit of adding digital breast tomosynthesis to digital mammography for breast cancer screening focused on cancer characteristics: a meta-analysis. *Breast Cancer Res Treat* 2017;164(3):557–569.
8. International Agency for Research on Cancer. *Handbook of Cancer Prevention*. Vol 15. Lyon, France: International Agency for Research on Cancer, 2016.
9. Hodgson R, Heywang-Köbrunner SH, Harvey SC, et al. Systematic review of 3D mammography for breast cancer screening. *Breast* 2016;27:52–61.
10. Houssami N, Miglioretti DL. Digital breast tomosynthesis: a brave new world of mammography screening. *JAMA Oncol* 2016;2(6):725–727.
11. Gilbert FJ, Tucker L, Young KC. Digital breast tomosynthesis (DBT): a review of the evidence for use as a screening tool. *Clin Radiol* 2016;71(2):141–150.
12. European Commission Initiative on Breast Cancer. *Recommendations from European Breast Guidelines*. <http://ecibc.jrc.ec.europa.eu/recommendations/list/3>. Accessed October 25, 2017.
13. Gilbert FJ, Tucker L, Gillan MG, et al. Accuracy of digital breast tomosynthesis for depicting breast cancer subgroups in a UK retrospective reading study (TOMMY trial). *Radiology* 2015;277(3):697–706.
14. Skaane P, Bandos AI, Eben EB, et al. Two-view digital breast tomosynthesis screening with synthetically reconstructed projection images: comparison with digital breast tomosynthesis with full-field digital mammographic images. *Radiology* 2014;271(3):655–663.
15. Bernardi D, Macaskill P, Pellegrini M, et al. Breast cancer screening with tomosynthesis (3D mammography) with acquired or synthetic 2D mammography compared with 2D mammography alone (STORM-2): a population-based prospective study. *Lancet Oncol* 2016;17(8):1105–1113.
16. Zuley ML, Guo B, Catullo VJ, et al. Comparison of two-dimensional synthesized mammograms versus original digital mammograms alone and in combination with tomosynthesis images. *Radiology* 2014;271(3):664–671.
17. Zuckerman SP, Conant EF, Keller BM, et al. Implementation of synthesized two-dimensional mammography in a population-based digital breast tomosynthesis screening program. *Radiology* 2016;281(3):730–736.
18. Hofvind S, Tsuruda K, Mangerud G, et al. The Norwegian Breast Cancer Screening Program, 1996-2016: celebrating 20 years of organised mammographic screening. In: *Cancer in Norway 2016—cancer incidence, mortality, survival and prevalence in Norway*. Oslo, Norway: Cancer Registry of Norway, 2017.
19. Goldhirsch A, Winer EP, Coates AS, Gelber RD, Piccart-Gebhart M, Thurlimann B, et al. Personalizing the treatment of women with early breast cancer: highlights of the St Gallen international expert consensus on the primary therapy of early breast cancer 2013. *Annals of oncology: official journal of the European Society for Medical Oncology / ESMO*. 2013;24:2206-23.
20. Clauser P, Nagl G, Helbich TH, et al. Diagnostic performance of digital breast tomosynthesis with a wide scan angle compared to full-field digital mammography for the detection and characterization of microcalcifications. *Eur J Radiol* 2016;85(12):2161–2168.
21. Timberg P, Baath M, Andersson I, Mattsson S, Tingberg A, Ruschin M. Visibility of microcalcification clusters and masses in breast tomosynthesis image volumes and digital mammography: a 4AFC human observer study. *Med Phys* 2012;39(5):2431–2437.
22. Friedewald SM, Rafferty EA, Conant EF. Breast cancer screening with tomosynthesis and digital mammography-reply. *JAMA* 2014;312(16):1695–1696.
23. Ciatto S, Houssami N, Bernardi D, et al. Integration of 3D digital mammography with tomosynthesis for population breast-cancer screening (STORM): a prospective comparison study. *Lancet Oncol* 2013;14(7):583–589.
24. Elmore JG, Longton GM, Carney PA, et al. Diagnostic concordance among pathologists interpreting breast biopsy specimens. *JAMA* 2015;313(11):1122–1132.
25. Rakha EA, Ahmed MA, Aleskandarany MA, et al. Diagnostic concordance of breast pathologists: lessons from the National Health Service Breast Screening Programme Pathology External Quality Assurance Scheme. *Histopathology* 2017;70(4):632–642.